

Exercise stress testing, myocardial perfusion imaging and stress echocardiography for detecting restenosis after successful percutaneous transluminal coronary angioplasty: a review of performance

G. DORI¹, Y. DENEKAMP¹, S. FISHMAN² & H. BITTERMAN¹

From the ¹Department of Internal Medicine A, Carmel Medical Center, Haifa, Israel; and Faculty of Medicine, and ²Faculty of Physics, Technion, Israel Institute of Technology, Haifa, Israel

Abstract. Dori G, Denekamp Y, Fishman S, Bitterman H (Carmel Medical Center, Haifa, Israel; Israel Institute of Technology, Israel). Exercise stress testing, myocardial perfusion imaging and stress echocardiography for detecting restenosis after successful percutaneous transluminal coronary angioplasty: a review of performance (Review). *J Intern Med* 2003; **253**: 253–262.

When chest symptoms recur in a patient who underwent percutaneous transluminal coronary angioplasty (PTCA), it is necessary to rule out restenosis (R). Three main noninvasive tests suggest the presence of R: exercise stress test (XT), myocardial perfusion imaging (MPI) and stress echocardiography (s-echo). The objectives of this review were: (1) to estimate the pretest probability of R as a function of time after PTCA in symptomatic patients and (2) to obtain an approximation of the diagnostic parameters of the XT, MPI and s-echo for detecting R. A MEDLINE search (English-language, years: 1980–2001) was conducted to identify studies examining post-PTCA functional testing for diagnosing R. Data from the studies were pooled. Comparing studies was often difficult due to varying methodology in

the studies. Pretest probability of R in symptomatic patients increases in a nonlinear fashion from 20% or less at 1 month, to nearly 90% at 1-year postangioplasty. The approximated accuracy of the XT, MPI, and s-echo for detecting R was 62, 82 and 84%, respectively. During the first month after PTCA, none of the noninvasive modalities is able to accurately detect R. Late (7–9 months) after PTCA, the pretest probability of R is high and therefore the noninvasive measure may be spared. Our analysis suggests that MPI and s-echo should be preferred over the XT for diagnosing R.

Keywords: diagnosis of restenosis, percutaneous transluminal coronary angioplasty, restenosis, stress testing.

Abbreviation: XT, exercise stress test; MPI, myocardial perfusion imaging; s-echo, stress echocardiography; PTCA, percutaneous transluminal coronary angioplasty; R, restenosis; AngR, angiographic restenosis; PPV, positive predictive value; NPV, negative predictive value; TP, true positive; TN, true negative; FP, false positive; FN, false negative.

Background

The era of interventional cardiology was launched by Dr Andreas Gruentzig in Zurich, 1977. Since then, this field has been growing rapidly in various aspects: the number of emerging treatment modalities, the initial success rate of the procedures, the amount of procedures performed per year and the total health care costs these treatments impose [1–5]. More than a million patients will undergo percutaneous transluminal coronary angioplasty (PTCA), worldwide, in the year 2002 [1]. The annual charge submitted to the parties paying for angioplasty exceeds 5 billion US\$, in the US alone [4–6]. Moreover, the amount of coronary angioplasties performed per year is expected to increase, as the process of ‘liberalization of indications for PTCA’ proceeds and as cardiologists become more assertive with increasing expertise [1, 7–12].

In contrast to the increasing experience with PTCA, it is somewhat frustrating that only modest improvement has been gained in control of restenosis (R). The latter is defined by many as the ‘Achilles heel’ of PTCA [13–17]. It occurs in 15–50% of the patients after an initially successful PTCA, most commonly within 6 months of the procedure and usually after a symptom-free period [18–22]. The introduction of coronary artery stenting had reduced the rate of R to <20% [23] and adjunctive therapy for stenting, namely brachytherapy [24], and drug coated stents [25] are under intensive evaluation and may further decrease R rate significantly. Thus, R imposes clinical and economic ‘taxes’ on the population undergoing PTCA. Clinically, in a significant fraction of patients the narrowing recurs, often expressed as chest pain, and economically, costs increase by roughly 20%, mainly due to the need for repeat revascularization [4, 6, 26, 27].

Preventing R, thereby decreasing the ‘taxes’, is potentially related to comprehensive understanding of the biology of R. Research activity in this field is intensive; however, these studies are expensive (estimated 1000–2000 US\$ per enrolled patient) due to the need for repeat coronary catheterizations of the patients as a gold standard for the diagnosis of R [2, 28]. A simple, low-priced, accurate, noninvasive tool to diagnose R could augment the volume of research in this field and possibly increase the odds of discovering the solution for this condition.

This analytical review is dedicated to the practitioner who encounters the difficulty of diagnosing

the cause of recurrent chest pain in patients who underwent an initially successful PTCA. Precise considerations regarding the multifaceted issue of diagnosing R are detailed [3]. Data on the available and commonly used noninvasive measures for the diagnosis of R are compiled in an attempt to answer the following practical clinical questions: (1) What is the pretest probability of R as a function of time after PTCA in symptomatic patients? (2) What are the diagnostic parameters (sensitivity, specificity, positive and negative predictive values) of the commonly available noninvasive measures for detecting R? Finally, arguments related to a practical approach to the work-up of a patient with recurrent chest pain after PTCA are discussed.

Methods

Literature search

By searching MEDLINE, we identified articles, which were published in the English language, from 1980 to 2001. The following key terms were used in the search: angioplasty, PTCA, R, detection, and diagnosis. The latter terms were also crossed with functional testing, exercise stress test (XT), myocardial perfusion imaging scan, scintigraphy and echocardiography. The identified studies were reviewed and selected references from these articles were reviewed as well.

Criteria for study inclusion and exclusion

Studies were included in the review if the following issues were explicitly reported by the authors: (1) study cohort underwent successful PTCA, (2) study cohort underwent a noninvasive diagnostic test and angiography, (3) criteria for determining test outcome (normal, abnormal or indeterminate) were explicitly described, (4) criteria for angiographic R (AngR) were reported, (5) the rate of AngR was reported and (6) the sensitivity and specificity (or the positive and negative predictive values) of the tests performed were reported. It is acknowledged that criteria defining outcomes may differ from one work to another, and sophisticated tests (MPI or s-echo) are usually performed after the more available tests (XT). Studies were excluded if: (1) the study group consisted of asymptomatic patients only, (2)

functional testing was conducted within 1 month after PTCA and (3) the noninvasive test was not followed by angiography.

Complexity of defining restenosis

Studies related to R may, at times, present conflicting data, and more commonly, comparing the results is difficult [9, 10, 17, 29]. This latter problem is related to issues which are 'variable' or controversial. Examining these issues in detail is beyond the scope of this review; however, some of them are inescapable, as they are directly related to the process of diagnosing R. For instance, more than a dozen different definitions for AngR exist [2, 17]. In the literature reviewed by us, AngR was determined as a $\geq 50\%$ diameter stenosis in 12 studies [7, 8, 28, 31, 34, 35, 41, 50, 51, 53, 54, 57], $\geq 70\%$ diameter stenosis in four studies [42, 44, 52, 58] and by other criteria (loss of gain) in four studies [16, 45, 55, 56]. This topic is not the only one with such a high variability. Definition of a successful PTCA, the adherence rate to study protocol, methods of angiogram analysis, end-points of studies, sequential work-up bias [30] and whether or not angiography is a gold standard for diagnosing R are among the prominent issues in dispute [2, 20, 31, 32]. Despite this complexity useful information for decision-making purposes must be extracted. Thus, it is obligatory to acknowledge the differences in the design and methods used in the various studies, validate results from several sources and thereby create a subjective overview regarding the practice of noninvasive diagnosis of R.

Detecting versus predicting R

Detecting or diagnosing R differs from predicting R [9, 33–36]. In this review, the terms detection and diagnosis are limited to describe whether R, according to a standard definition, is present at the time the noninvasive test is employed [9]. Specifically, the gold standard test (angiography) is performed shortly after the noninvasive test, to reveal whether R was or was not present when the latter was performed. In contrast, prediction is related to the future occurrence of R [33, 36]. There is no intention to underestimate the importance of predicting R; however, in this review we concentrate on the measures available for diagnosing it.

Target population

Patients after successful PTCA may be classified into three groups: (1) patients having no R, (2) patients having asymptomatic R or (3) patients having symptomatic R. From a practical clinical point of view, the group that gains most of the attention is the third one, because their discomfort must be attended to. With respect to the fact that PTCA is mainly a symptom-palliating procedure, the issue whether R in asymptomatic patients warrants further noninvasive intervention is unsettled [10, 15, 23, 31, 40, 41]. Thus, symptomatic patients after an initially successful PTCA are the target population in this review.

As the patients involved are symptomatic it is natural to question whether the recurrence of chest pain attests to the presence of R. However, it was widely demonstrated that chest pain is not sufficiently sensitive nor specific for diagnosing R [14, 37, 41, 42]. Hence, the issue of chest pain as a marker of R is excluded from this review.

Detecting restenosis within 1 month after PTCA

Accurate detection of R in the target population, using the noninvasive measures, within 1 month after PTCA, is unlikely, mainly due to a high rate of false positive (FP) results [9, 28, 33, 36, 37, 45–48]. Hence, this review focuses on studies in which measures to diagnose R were performed 1–9 months after an initially successful PTCA.

The significance of diagnostic parameters for the individual patient

Sensitivity and specificity determine the quality of a test [43]. Sensitivity, in the context of this review, determines the rate by which a test truly rules-in patients with R, whilst specificity determines the rate by which a test truly rules-out patients without R. However, the practitioner and the patient are interested in different diagnostic parameters [43, 44]. They want to know the probability of R, given a positive (abnormal) or a negative (normal) test result. This probability is also termed post-test probability, and is described by the positive and negative predictive values (PPV and NPV, respectively). PPV and NPV are mathematically related to sensitivity and specificity, and the prevalence of the

disease. The prevalence of R reflects the probability of R in an investigated population, also termed pretest probability. To conclude, most studies report the performance of a test employing sensitivity and specificity. However, to utilize this in favour of the individual patient, an evaluation of the pretest probability is obligatory (for a broader discussion see Gibbons *et al.* [40]). Importantly, one must acknowledge that deducing diagnostic parameters from a uniquely designed study to a specific patient is not trivial. This is due to the difference in clinical, procedural and methodological variables of the study group from those of the patient's. Therefore, at least the major variables affecting this inference should be acknowledged. One of the important variables is the pretest probability of R after PTCA.

Results

Pretest probability of restenosis

The rate by which the target population becomes symptomatic varies as a function of time after PTCA. Figure 1 compiles data from nine studies on the percentage of patients becoming symptomatic (*y*-axis) versus time after PTCA (*x*-axis). The superimposed curve may only serve as a coarse estimate of the trend of the data set, demonstrating an increase in symptomatic patients, towards 20–40%, approximately 5–6 months after PTCA. At 1 year after PTCA, less patients are symptomatic (approximately 20–30%) [15]. Figure 2 compiles data on the rate of R in symptomatic patients (*y*-axis) as a function of time

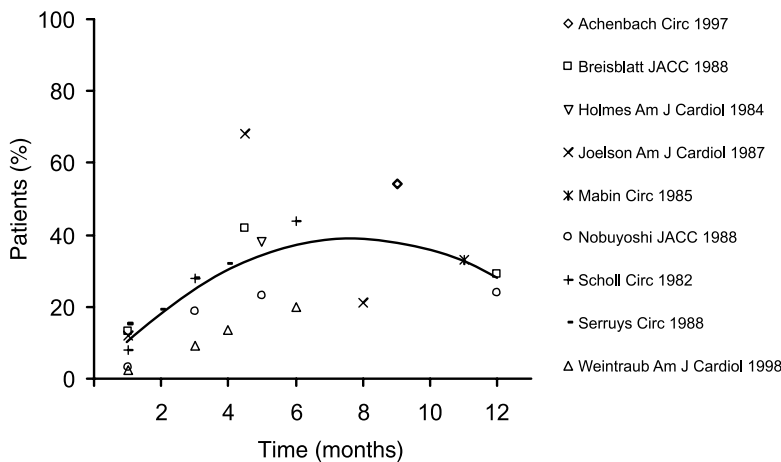


Fig. 1 Percentage of patients with symptoms as a function of time after successful PTCA.

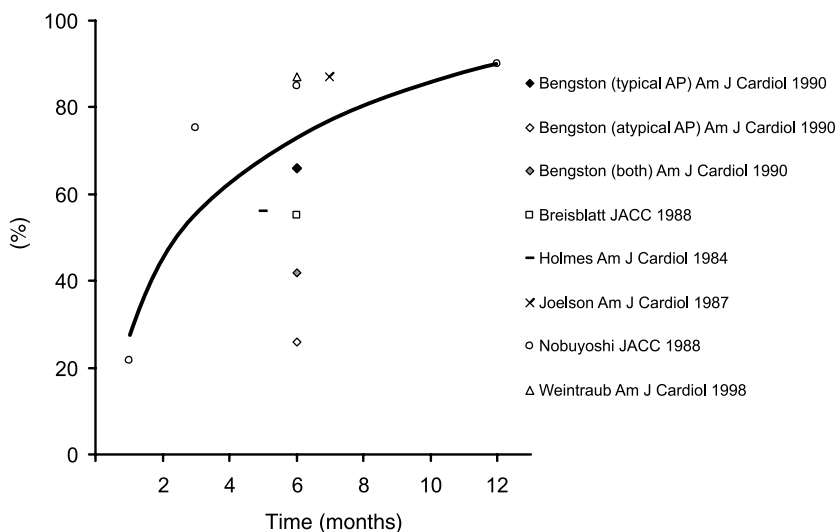


Fig. 2 Percentage of restenosis in symptomatic patients as a function of time after successful PTCA.

after PTCA (*x*-axis) as determined by the accepted gold standard test (angiography) [2, 28, 40]. Data for constructing this graph are limited. Here also, the superimposed curve represents only a general tendency of the data set. Figure 2 represents the pretest probability of R in the target population. One can see that the pretest probability in this group of patients varies dramatically from approximately 20% or less at 1 month, to nearly 90% at 1-year evaluation. This change in pretest probability as a function of time after PTCA significantly affects the calculated PPV and NPV for a given sensitivity and specificity. The implication is strongest early after PTCA.

Exercise stress testing

The XT is the most commonly utilized measure for evaluating patients after PTCA [37, 49]. Exercise stress testing was used for detecting R in 14 studies (see appendix for raw data). The stress was induced by walking on a treadmill, exercising on stationary bicycles or administering dobutamine, in nine [7, 8, 16, 41, 42, 44, 45, 50, 51], three [31, 52, 53] and three [28, 35, 54] studies, respectively. Restenosis evaluation was performed approximately 6 months (range: 3–8) after angioplasty. The characteristics of the patients recruited to the studies varied. In three studies patients had a single vessel disease, whereas in all the other studies patients suffered from a multivessel disease. The pretest probability for R, defined as the rate of AngR, varied from 16 to 79%. The angiographic criteria for determining AngR varied as well, although most studies used the >50% diameter stenosis as the criterion.

It is clear that comparing the data from the various studies is not straightforward due to the

heterogeneity of the study groups, angiographic definitions, regimens of medication and timing of evaluations, amongst other confounding factors. If one is willing to tolerate these differences, then the data may be pooled [43]. In this process the true positive (TP), true negative (TN), FP, and false negative (FN) results obtained for each test are summed [43]. This summation is performed in order to answer the important clinical question: what is the postexercise test probability of R in symptomatic patients approximately 6 months after an initially successful PTCA?

A total of 1192 patients and arterial lesions were pooled from 14 studies (Appendix 1). The pooled rate of AngR was 49%. Of the 498 abnormal XT, 317 were TP (64%). Of the 694 normal XT, 423 were TN (61%). Table 1 summarizes the range of, and the pooled values of the diagnostic parameters.

Myocardial perfusion scan

Myocardial perfusion imaging scan was used for detecting R in nine studies. The stress was induced by walking on a treadmill, exercising on stationary bicycles or administering dobutamine, in four [7, 8, 55, 56], two [50, 52] and three [34, 35] studies, respectively. In a unique study, Hoffmann and co-workers induced stress by transoesophageal atrial pacing [31]. In all nine studies R was evaluated approximately 6.6 months (range: 4–11) after angioplasty. The pretest probability for R, defined as the rate of AngR, varied from 16 to 65%. The angiographic criteria for determining AngR varied as well, although most studies used the >50% diameter stenosis as the criterion.

Table 1 Summary of diagnostic parameters for XT, MPI and s-echo

Measure	Sensitivity	Specificity	PPV	NPV	Total accuracy
XT					
Range	24–93	31–100	42–100	28–95	
Pooled result	54	70	64	61	62
MPI					
Range	74–100	62–93	50–89	82–100	
Pooled result	83	79	80	85	82
s-echo					
Range	38–95	79–95	59–98	62–92	
Pooled result	82	86	88	79	84

Total accuracy is defined as the number of true results (positive and negative) over the total number of tests. XT, exercise stress test; MPI, myocardial perfusion imaging; s-echo, stress echocardiography; PPV, positive predictive value; NPV, negative predictive value.

The data from the studies reviewed in this section were pooled, under the precautions stated above (see Appendix 1). The question is: what is the post-MPI probability of R in symptomatic patients approximately 6 months after an initially successful PTCA?

The number of patients and vessels that were compiled was 451 (Appendix 1). AngR rate was 49%. Of the 239 abnormal MPI tests, 191 (80%) were TP, whilst 48 (20%) were FP. Of the 212 normal MPI tests 181 (85%) were TN whilst 31 (15%) were FN. Table 1 summarizes the range of, and the pooled values of, the diagnostic parameters.

Stress echocardiography

The role of stress echocardiography (s-echo) in detecting R was investigated in a limited number of studies. More studies involving s-echo were performed to assess the extent of revascularization and to predict R (see Table 2 in Rosanio *et al.* [37]). The stress was induced by exercising on stationary bicycles in three studies [50, 53, 57], administering dobutamine in two studies [54, 58], exercising on a treadmill in one study [41] and by atrial pacing in one study [31]. On the average, in all seven studies R was evaluated 6 months (range: 3–8) after angioplasty (Appendix 1). The pretest probability of R, defined as the rate of AngR, varied from 30 to 79%. Most studies used the >50% diameter stenosis criterion for determining AngR. As in the sections above, the issue is the post-s-echo probability of R in symptomatic patients approximately 6 months after an initially successful PTCA?

A total of 623 patients and vessels were pooled. Rate of AngR was 56%. Of the 327 abnormal s-echo results, 288 (88%) were TP, whilst 39 (12%) were FP. Of the 296 normal s-echo results 233 (79%) were TN, whilst 63 (21%) were FN. Table 1 summarizes the range of, and the pooled values of the diagnostic parameters.

Discussion

Fourteen studies related to the role of XT in detecting R after successful PTCA were reviewed. Similarly, nine and seven studies were reviewed for MPI and s-echo, respectively. The results are summarized in Table 1 and below.

Pretest probability of restenosis in symptomatic patients as a function of time after successful PTCA

Accurate figures are difficult to obtain; however, Fig. 2 may be cautiously used to depict this probability. One month after PTCA this probability is low, in the range of 10–20%, but sharply increases in the subsequent 4–5 months, towards 60–80%. From the sixth to the twelfth month after PTCA this probability continues to increase, however, less steeply. One should note that the range associated with the values in Fig. 2 is large. It is also apparent from the limited amount of data in Fig. 2 that interpolation in between the data points may be required in order to evaluate a specific patient.

Diagnostic parameters of the three noninvasive modalities

Table 1 summarizes the 'pooled' diagnostic parameters of the three modalities for detecting R. In general, one can see that MPI and s-echo are superior to XT in every diagnostic parameter, including total accuracy. Specifically, in the comparative studies (comparing at least two diagnostic modalities, e.g. XT and MPI, in the same study cohort) the diagnostic parameters of the MPI and s-echo were always superior to those of the XT [7, 8, 31, 41, 50, 52, 53]. The PPV and NPV of XT are both in the domain of 60%, thus XT cannot reliably be used to either rule-in or rule-out patients with R. Similar pooled values of sensitivity and specificity were reported in a meta-analysis by Garzon *et al.* [29].

Limitations of study

The pooled results are easier to relate to, as a single value is available instead of a wide range of values. However, these values may be misleading, as they were derived from different studies representing various patient populations. Nevertheless, we believe that these pooled diagnostic parameters are useful as a first approximation of the post-test probability of R. Indeed, this post-test probability may not replace a specific, thorough clinical evaluation for each patient. In the studies reviewed here sensitivity and specificity were obtained from unique clinical set-ups and for specific groups of patients. Based on these reports we tend to generalize the results to a wider spectrum of clinical conditions, not

always compatible with the original scientific source. This is due to the difficulty of remembering the clinical characteristics, inclusion and exclusion criteria of all the studies, that is required in order to be able to use the most appropriate test results for a specific patient. Hence the pooled diagnostic parameters offer a first measure of the post-test probability of R, after which individual clinical considerations should be incorporated.

A serious deficit is the lack of data from the earlier period after PTCA. One may see from Fig. 2 that most of the data derived at around 6 months after PTCA, a time where R is expected to be present angiographically, had it developed. This obligates the reader to interpolate the sensitivity and specificity results obtained at 6 months, to those at earlier periods. This process, however, may be misleading, and at best may approximate reality. This point of criticism, obviously, holds true for the diagnostic parameters calculated for the pooled data. That is why we relate to these values as first approximation.

The studies reviewed here almost always contained asymptomatic patients, which results in 'dilution' of the higher risk population by a lower risk population. Thus, the results reported in this review may serve as a lower limit to what we would have obtained, had we reviewed studies related to symptomatic patients only.

Suggested arguments for a practical approach to a patient with recurrent chest pain after successful PTCA

Developing a flow-chart algorithm for evaluating patients with recurrent chest pain after PTCA is complex, as many clinical and procedural variables must be taken into consideration. Nevertheless, detailed history, physical examination, assessment of pretest and post-test probabilities are milestones in this process. A few issues are pointed out that, in our opinion, deserve special attention.

The first month after PTCA

From the literature reviewed, it appears that all noninvasive methods for detecting R are quite noninformative throughout the first month after PTCA, mainly due to high rates of FP results [10, 37]. Although the pretest probability of R at this period is low the noninvasive tools cannot reliably confirm

either the presence of R or the success of revascularization. In their comprehensive review of the role of MPI after PTCA, Miller *et al.* emphasized the significant rate of FP results early after PTCA. This outcome precludes obtaining a high PPV for MPI at this early evaluation [10]. Thus, unfortunately this period is truly 'problematic' for diagnosing R [5, 10, 47, 48]. The practitioner confronting the patient presenting with early recurrence of symptoms may proceed with angiography. The benefits versus the risks of the procedure must be carefully weighed.

Late after PTCA

On the other side of the spectrum, if a patient reports recurrent effort-induced chest pain, 6–9 months after a successful dilatation, the pretest probability of R is high approaching 70–90%. One must consider what is the added value of a noninvasive test, in such cases [29]. It may be appropriate to refer the patient for angiographic evaluation, sparing the noninvasive diagnostic stage.

Exercise stress test – if at all?

The XT may be the appropriate modality to detect R in a selected group of patients, namely those with single vessel disease and normal rest ECG [11]. This approach was reported to be adopted by many, although not objectively tested [10]. The only study in favour of this approach was the one performed by El-tamimi *et al.* [16], which is exceptional for its results. Therefore, we cannot conclude that broad evidence is available to support this approach, even in this selected group of patients.

Myocardial perfusion imaging versus stress echocardiography

From the individual studies reviewed, and Table 1, it appears that s-echo performance is similar to MPI as a measure for detecting R. Thus, the selection of the procedure of choice should depend on local availability, quality of testing at the specific centre [35, 53] and the cost of each test [28].

Diagnosing in-stent restenosis

Few studies refer to the issue of diagnosing R in the stented artery [59, 60]. Although data are limited it

appears that the MPI is an accurate tool for detecting R, whereas the XT is much less sensitive and specific. Sound conclusions cannot be drawn at the present time.

'Silent' restenosis

The investigation was restricted to symptomatic patients, mainly because this group seeks medical help, and the prognosis of the asymptomatic group is good [26, 38, 39]. The XT, MPI and s-echo were evaluated as tools for diagnosing 'silent R' [49, 61–63]; however, the data are limited. In cases where vessel patency must be assessed, either XT or MPI may be performed. These tests have high negative predictive values, 95 and 98%, respectively [63]. Thus, if the test is normal, the probability of R is very low (<5%). In contrast, the positive predictive values of XT and MPI in 'silent R' are low (53 and 63%, respectively) [63, 64].

Future prospects

The studies reviewed here demonstrate the usefulness and limitations of the three standard noninvasive modalities for detecting R, after successful PTCA. These modalities electively induce myocardial ischaemia, aiming to detect pathological tissue response to this challenge. The diagnosis of R depends on this abnormal functional response. However, the correlation between this response and the presence of R is, at times, limited, especially early after PTCA. Thus, perhaps future modalities should rely on a different principle. In this regard, one example that comes to mind is that of the contrast enhanced electron beam computed tomography. With its use the coronary tree is noninvasively imaged, with sensitivity of 94% and specificity of 82% [65]. However, this modality is expensive and not free from limitations. If a noninvasive, accurate, low-priced measure to detect R could be developed, it would surely fulfil a diagnostic need.

Acknowledgements

G.D. is grateful for the support received from the Foulkes Foundation, London, UK.

Grant support: This study was supported in part by the Ministry of Health of Israel (grant no. 3742).

References

- 1 Bittl JA. Advances in coronary angioplasty. *N Engl J Med* 1996; **335**: 1290–302.
- 2 Kuntz RE, Baim DS. Defining coronary restenosis newer clinical and angiographic paradigms. *Circulation* 1993; **88**: 1310–23.
- 3 Califf RM, Fortin DF, Frid DJ *et al.* Restenosis after coronary angioplasty: an overview. *J Am Coll Cardiol* 1991; **17**: 2b–13b.
- 4 Topol EJ, Ellis SG, Cosgrove DM *et al.* Analysis of coronary angioplasty practice in the united states with an insurance-claims data base. *Circulation* 1993; **87**: 1489–97.
- 5 Scanlon PJ, Faxon DP, Audet AM *et al.* ACC/AHA guidelines for coronary angiography. *J Am Coll Cardiol* 1999; **33**: 1756–824.
- 6 Cohen DJ, Krumholz HM, Sukin CA *et al.* In-hospital and one-year economic outcomes after coronary stenting or balloon angioplasty. Results from a randomized clinical trial. *Circulation* 1995; **92**: 2480–7.
- 7 Georgoulas P, Demakopoulos N, Kontos A *et al.* Tc-99m tetrofosmin myocardial perfusion imaging before and six months after percutaneous coronary angioplasty. *Clin Nuc Med* 1998; **23**: 678–82.
- 8 Hecht HS, Shaw RE, Bruce TR, Ryan C, Stertzer SH, Myler RK. Usefulness of tomographic Thallium-201 imaging for detection of restenosis after percutaneous transluminal coronary angioplasty. *Am J Cardiol* 1990; **66**: 1314–8.
- 9 Mishra JP, Iskandrian AE. Stress myocardial perfusion imaging after coronary angioplasty. *Am J Cardiol* 1998; **81**: 766–9.
- 10 Miller DD, Verani MS. Current status of myocardial perfusion imaging after percutaneous transluminal coronary angioplasty. *J Am Coll Cardiol* 1994; **24**: 260–6.
- 11 Holmes DR. Very early prediction of restenosis after successful coronary angioplasty: How early is early and can we identify it? *J Am Coll Cardiol* 1990; **15**: 265–6.
- 12 Ischinger T, Gruentzig AR, Hollman J *et al.* Should coronary arteries with less than 60% diameter stenosis be treated by angioplasty? *Circulation* 1983; **68**: 148–54.
- 13 Currier JW, Faxon DP. Restenosis after percutaneous transluminal coronary angioplasty: have we been aiming at the wrong target? *J Am Coll Cardiol* 1995; **25**: 516–20.
- 14 Gruentzig A, King SB III, Schlumpf M, Siegenthaler W. Long-term follow-up after percutaneous transluminal coronary angioplasty. The early Zurich experience. *N Engl J Med* 1987; **316**: 1127–32.
- 15 Weintraub WS, Ghazzal ZM, Douglas JS, Morris DC, King SB 3rd. Usefulness of the substitution of nonangiographic end points (death, acute myocardial infarction, coronary bypass and/or repeat angioplasty) for follow-up coronary angiography in evaluating the success of coronary angioplasty in patients with angina pectoris. *Am J Cardiol* 1998; **81**: 382–6.
- 16 El-Tamimi H, Davies GJ, Hackett D, Fragasso G, Crea F, Maseri A. Very early prediction of restenosis after successful coronary angioplasty: anatomic and functional assessment. *J Am Coll Cardiol* 1990; **15**: 259–64.
- 17 Serruys PW, Luijten HE, Beatt KJ *et al.* Incidence of restenosis after successful coronary angioplasty: a time-related phenomenon. A quantitative angiographic study in 342 consecutive patients at 1,2,3, and 4 months. *Circulation* 1988; **77**: 361–371.

- 18 Kaltenbach M, Kober G, Scherer D, Vallbracht C. Recurrence rate after successful coronary angioplasty. *Eur Heart J* 1985; **6**: 276–81.
- 19 Leimgruber PP, Roubin GS, Hollman J *et al*. Restenosis after successful coronary angioplasty on patients with single-vessel disease. *Circulation* 1986; **73**: 710–7.
- 20 Serruys PW, Foley DP, Kirkeedie RL, King SB III Restenosis revisited: insights provided by quantitative coronary angioplasty. *Am Heart J* 1993; **126**: 1243–67.
- 21 Nobuyoshi M, Kimura T, Nosaka H *et al*. Restenosis after successful percutaneous transluminal coronary angioplasty: serial angiographic follow-up of 229 patients. *J Am Coll Cardiol* 1988; **12**: 616–23.
- 22 O'meara JJ, Dehmer GJ. Care of the patient and management of complications after percutaneous coronary artery interventions. *Ann Intern Med* 1997; **127**: 458–71.
- 23 Mercado N, Boersma E, Wijns W *et al*. Clinical and quantitative coronary angiographic predictors of coronary restenosis: a comparative analysis from the balloon-to-stent era. *J Am Coll Cardiol* 2001; **38**: 645–52.
- 24 Ashby DT, Dangas G, Mehran R, Leon MB. Coronary artery stenting. *Catheter Cardiovasc Interv* 2002; **56**: 83–102.
- 25 Harding SA, Walters DL, Palacios IF, Oesterle SN. Adjunctive pharmacotherapy for coronary stenting. *Curr Opin Cardiol* 2001; **16**: 293–9.
- 26 Weintraub WS, Ghazzal ZMB, Douglas JS Jr *et al*. Long-term clinical follow-up in patients with angiographic restudy after successful angioplasty. *Circulation* 1993; **87**: 831–40.
- 27 Gilbert SP, Weintraub WS, Talley DJ, Boccuzzi SJ. Costs of coronary restenosis (Lovastatin restenosis trial). *Am J Cardiol* 1996; **77**: 196–9.
- 28 Coma-Canella I, Daza NS, Orbe LC. Detection of restenosis with dobutamine stress test after coronary angioplasty. *Am Heart J* 1992; **124**: 1196–204.
- 29 Garzon P, Eisenberg MJ. Functional testing for the detection of restenosis after percutaneous transluminal coronary angioplasty: a meta-analysis. *Can J Cardiol* 2001; **17**: 41–8.
- 30 Lauer MS. Role of stress testing and cardiac imaging in patients who have undergone previous coronary revascularization. *Cardiol Rev* 2000; **8**: 158–65.
- 31 Hoffmann R, Kleinhans E, Lambertz H *et al*. Transesophageal pacing echocardiography for detection of restenosis after percutaneous transluminal coronary angioplasty. *Eur Heart J* 1994; **15**: 823–31.
- 32 Bourassa MG, Lesperance J, Eastwood C *et al*. Clinical, physiologic, anatomic and procedural factors predictive of restenosis after percutaneous transluminal coronary angioplasty. *J Am Coll Cardiol* 1991; **18**: 368–76.
- 33 Breisblatt WM, Weiland FL, Spaccavento LJ. Stress thallium-201 imaging after coronary angioplasty predicts restenosis and recurrent symptoms. *J Am Coll Cardiol* 1988; **12**: 1199–204.
- 34 Caner B, Oto A, Ovunc K, Kirtli P. Prediction of restenosis after successful percutaneous coronary angioplasty by dobutamine thallium-201 scintigraphy. *Int J Cardiol* 1998; **66**: 175–81.
- 35 Elhendy A, Geleijnse ML, Roelandt JRTC *et al*. Dobutamine Tc-MIBI SPET myocardial perfusion scintigraphy in the prediction of restenosis after percutaneous transluminal coronary angioplasty in patients unable to perform an exercise test. *Nuclear Med Comms* 1997; **18**: 122–8.
- 36 Wijns W, Serruys PW, Reiber JHC *et al*. Early detection of restenosis after successful percutaneous transluminal coronary angioplasty by exercise-redistribution Thallium scintigraphy. *Am J Cardiol* 1985; **55**: 357–61.
- 37 Rosanio S, Tocchi M, Stouffer GA. Use of stress testing to evaluate patients with recurrent chest pain after percutaneous coronary revascularization. *Am J Med Sci* 1998; **316**: 46–52.
- 38 Hernandez RA, Macaya C, Iniguez A *et al*. Midterm outcome of patients with asymptomatic restenosis after coronary balloon angioplasty. *J Am Coll Cardiol* 1992; **19**: 1402–9.
- 39 Weintraub WS, Ghazzal ZMB, Douglas JS Jr *et al*. Initial management and long-term clinical outcome of restenosis after initially successful percutaneous transluminal coronary angiography. *Am J Cardiol* 1992; **70**: 47–55.
- 40 Gibbons RJ, Balady GJ, Beasley JW *et al*. ACC/AHA guidelines for exercise testing. *J Am Coll Cardiol* 1997; **30**: 280–315.
- 41 Crouse LJ, Vacek JL, Beauchamp GD, Kramer PH. Use of exercise echocardiography to evaluate patients after coronary angioplasty. *Am J Cardiol* 1996; **78**: 1163–6.
- 42 Bengtson JR, Mark DB, Honan MB *et al*. Detection of restenosis after elective percutaneous transluminal coronary angioplasty using exercise treadmill test. *Am J Cardiol* 1990; **65**: 28–34.
- 43 Diamond GA, Forrester JS. Analysis of probability as an aid in the clinical diagnosis of coronary-artery disease. *N Engl J Med* 1979; **300**: 1350–8.
- 44 Honan MB, Bengtson JR, Pryor DB *et al*. Exercise treadmill testing is a poor predictor of anatomic restenosis after angioplasty for acute myocardial infarction. *Circulation* 1989; **80**: 1585–94.
- 45 Michaelides AP, Dilaveris PE, Psomadaki ZD *et al*. Reliability of the exercise-induced ST-segment changes to detect restenosis three months after coronary angioplasty: significance of the appearance of other leads. *Am Heart J* 1998; **135**: 449–56.
- 46 DePuey GE, Leatherman LL, Leachman RD *et al*. Restenosis after transluminal coronary angioplasty detected with exercise-gated radionuclide ventriculography. *J Am Coll Cardiol* 1984; **4**: 1103–13.
- 47 Flachs Kampf FA, Hoffmann R, Vom Dahl J, Lethen H, Hanrath P. Functional assessment of PTCA results by stress echocardiography: when and how to test. *Eur Heart J* 1995; **16**: 31–4.
- 48 Manyari DE, Knudtson M, Kloiber R, Roth D. Sequential thallium-201 myocardial perfusion studies after successful percutaneous transluminal coronary artery angioplasty: delayed resolution of exercise-induced scintigraphic abnormalities. *Circulation* 1988; **77**: 86–95.
- 49 Laarman G, Luijten HE, van Zeyl LGPM *et al*. Assessment of silent restenosis and long-term follow-up after successful angioplasty in single vessel coronary artery disease: the value of quantitative exercise electrocardiography and quantitative coronary angiography. *J Am Coll Cardiol* 1990; **16**: 578–85.
- 50 Takeuchi M, Miura Y, Toyokawa T, Araki M, Nakashima Y, Kuroiwa A. The comparative diagnostic value of dobutamine stress echocardiography and thallium stress tomography for detecting restenosis after coronary angioplasty. *J Am Soc Echocardiogr* 1995; **8**: 696–702.
- 51 Malekianpour M, Rodes J, Cote G *et al*. Value of exercise electrocardiography in the detection of restenosis after coronary angioplasty in patients with one-vessel disease. *Am J Cardiol* 1999; **84**: 258–63.

- 52 Ernst SMPG, Hillebrand FA, Klein B, Ascoop CA, van Tellin-gen C, Plokker HWM. The value of exercise tests in the follow-up of patients who underwent transluminal coronary angioplasty. *Int J Cardiol* 1985; **7**: 267–79.
- 53 Hecht HS, DeBord L, Shaw RE *et al.* Usefulness of supine bicycle stress echocardiography for detection of restenosis after percutaneous transluminal coronary angioplasty. *Am J Cardiol* 1993; **71**: 293–6.
- 54 Heinle SK, Lieberman EB, Ancukiewicz M, Waugh RA, Bashore TM, Kisslo J. Usefulness of dobutamine echocardiography for detecting restenosis after percutaneous transluminal coronary angioplasty. *Am J Cardiol* 1993; **72**: 1220–5.
- 55 Milan E, Zoccarato O, Terzi A *et al.* Technetium-99m-sestamibi SPECT to detect restenosis after successful percutaneous transluminal coronary angioplasty. *J Nucl Med* 1996; **37**: 1300–5.
- 56 Kostkiewicz M, Jarosz W, Tracz W *et al.* Thallium-201 myocardial perfusion imaging in patients before and after successful percutaneous transluminal coronary angioplasty. *Int J Cardiol* 1996; **53**: 299–304.
- 57 Mertes H, Erbel R, Nixdorff U, Mohr-Kahaly S, Kruger S, Meyer J. Exercise echocardiography for the evaluation of patients after nonsurgical coronary artery revascularization. *J Am Coll Cardiol* 1993; **21**: 1087–93.
- 58 Scherhag AW, Pfeleger S, Schreckenberger AB *et al.* Detection of patients with restenosis after PTCA by dipyridamole- atropine-stress-echocardiography. *Int J Cardiac Imaging* 1997; **13**: 115–23.
- 59 Kosa I, Blasini R, Schneider-Eicke J *et al.* Myocardial perfusion scintigraphy to evaluate patients after coronary stent implantation. *J Nucl Med* 1998; **39**: 1307–11.
- 60 Milavetz JJ, Miller TD, Hodge DO, Holmes DR, Gibbons RJ. Accuracy of single photon emission computed tomography myocardial perfusion imaging in patients with stents in native coronary arteries. *Am J Cardiol* 1998; **82**: 857–61.
- 61 Desmet W, De Scheerder I, Piessens J. Limited value of exercise testing in the detection of silent restenosis after successful coronary angioplasty. *Am Heart J* 1995; **129**: 452–9.
- 62 Pirelli S, Danzi GB, Alberti A *et al.* Comparison of usefulness of high-dose dipyridamole echocardiography and exercise echocardiography for detection of asymptomatic restenosis after coronary angioplasty. *Am J Cardiol* 1991; **67**: 1335–8.
- 63 Schroeder E, Marchandise B, De Coster P *et al.* Detection of restenosis after coronary angioplasty for single-vessel disease: how reliable are exercise electrocardiography and scintigraphy in asymptomatic patients? *Eur Heart J* 1989; **10** (Suppl. G): 18–21.
- 64 Deshpande NV, Serruys PW. Asymptomatic restenosis: should we (re) intervene? An unresolved diemna. *Am Heart J* 1998; **136**: 576–7.
- 65 Achenbach S, Moshage W, Bachmann K. Detection of high-grade restenosis after PTCA using contrast-enhanced electron beam CT. *Circulation* 1997; **96**: 2785–8.

Appendix 1

Pooled data summarizing the diagnostic parameters of the tests for detecting restenosis

Exercise stress test			
Fourteen studies [7, 8, 16, 28, 31, 35, 41, 42, 44, 45, 51–54]			
No. of tests performed:	1192	AngR	NR
588 (49.3%)		604 (50.7%)	
XT – Abnormal		TP	FP
498 (41.8%)		317	181
XT – Normal		FN	TN
694 (58.2%)		271	423
Myocardial perfusion imaging			
Nine studies [7, 8, 31, 34, 35, 50, 52, 55, 56]			
No. of tests performed:	451	AngR	NR
MPI – Abnormal		222 (49.2%)	229 (50.8%)
239 (53%)		TP	FP
MPI – Normal		191	48
212 (47%)		FN	TN
		31	181
Stress echocardiography			
Seven studies [31,41,50,53, 54,57,58]			
No. of tests performed:	623	AngR	NR
s-echo – Abnormal		351 (56.3%)	272 (43.7%)
327 (52.5%)		TP	FP
s-echo – Normal		288	39
296 (47.5%)		FN	TN
		63	233

AngR, angiographic restenosis; NR, no AngR; TP, true positive; TN, true negative; FP, false positive; FN, false negative; XT, exercise stress test; MPI, myocardial perfusion imaging; s-echo, stress echocardiography.

Received 19 August 2002; revision received 1 November 2002; accepted 26 November 2002

Correspondence: Guy Dori, Department of Internal Medicine A, Carmel Medical Center, 7, Michal St, Haifa 34362, Israel (fax: +972-54-348-734; e-mail: g_dori@bezeqint.net).